



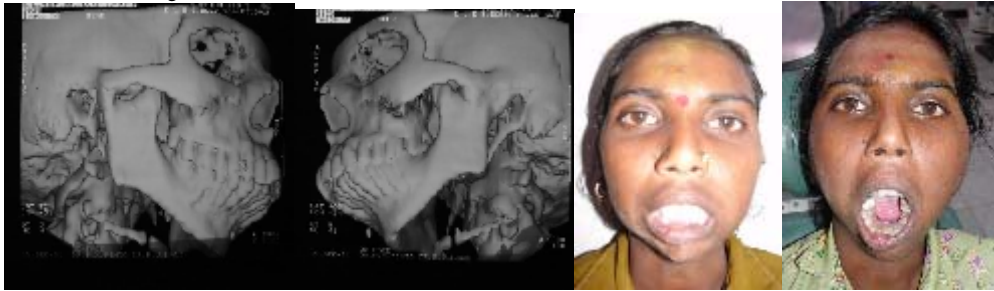PRE

POST

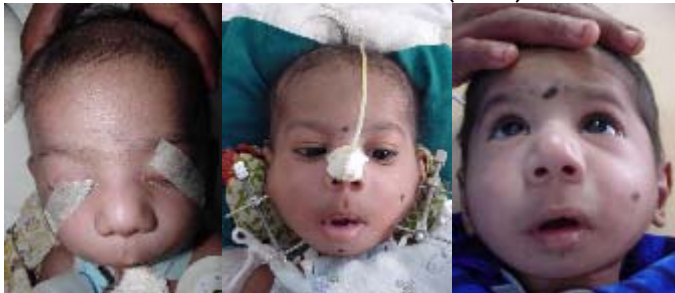
TMJ Ankylosis

Before

After



Mandibular Distraction (DO) in Infant (First Time in Karnataka)



Before

During DO

After

Cleft Lip and Palate

