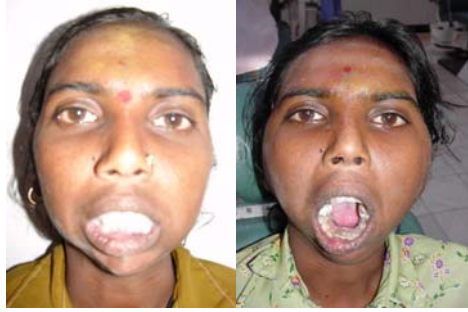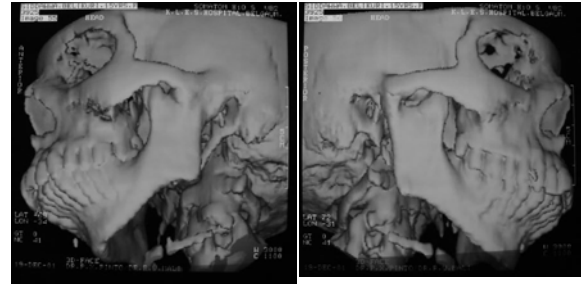


TMJ Ankylosis

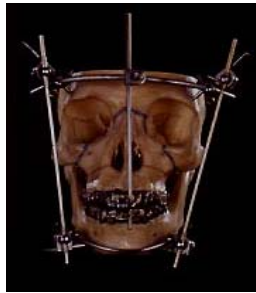

Before

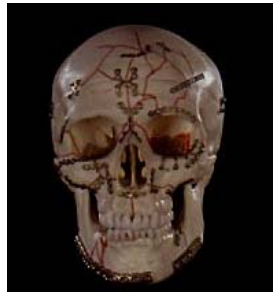
After



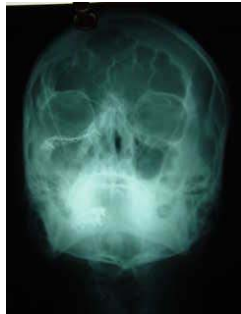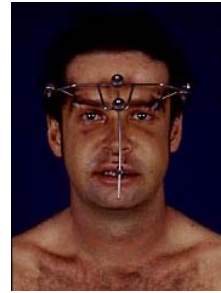CRANIOFACIAL TRAUMA



Ext Fixation (OLD)



Int Fixation (NEW)



ORBITAL TRAUMA

